


Short Communication

Physician Modified Infusion Catheter (PMIC): An innovation to make catheter directed thrombolysis (CDT) more accessible

Ahmed MT Ghanem*

Abstract

Catheter directed thrombolysis is the most compatible technique for management of acute ischemia especially acute on top of chronic acute lower limb ischemia, DVT and pulmonary embolism. Herein, we manufacture a physician modified infusion catheter that make the catheter directed thrombolysis more applicable and widely accessible.

Keywords: Infusion catheter; Catheter directed thrombolysis; Physician modified Catheter; Acute Ischemia; DVT

Abbreviations list

Physician Modified Infusion Catheter (PMIC)

Catheter Directed Thrombolysis (CDT)

Pulmonary Embolism (PE)

Deep Venous Thrombosis (DVT)

Surgical technique and innovation

Catheter directed thrombolysis (CDT) is the first choice treatment in many centers for patients with marginally threatened ALI and in patients with serious disabling symptoms of not immediately threatening limb ischemia [1].

Specially, that there is a high rate of perioperative complications in vascular patients undergoing open surgical revascularization [2]. So, the success can be achieved with an acceptable complication rate in many patients, especially those with fresh thrombus or emboli [3].

For me, CDT seems to be the most compatible technique with the pathological nature of the thrombosis especially the acute on top of chronic lower limb ischemia. It could be used also in the treatment of deep venous thrombosis (DVT) and pulmonary Embolism (PE). Herein we manufactured a simple infusion catheter called physician modified infusion catheter. Our aim is to make the infusion catheter available at any time and to make the procedure more universal.

We use the 4F or 5F angiographic catheter and then we modify it. We prefer Catheters from Cordis (Johnson & Johnson) because it is harder and can tolerate the manually created multiple pores very well. The fenestrations created by rolling a syringe needle (25 Gauge) slowly and patiently till the needle crosses the catheter to the other side (Figure 1).

Recurring the maneuver up to the needed length of the fenestrations then repeated flushing by heparinized saline (Figure 2) followed by sliding the catheter over the hydrophilic Terumo wire.

Affiliation:

Vascular Surgery Department, Nasser Institute For Research And Treatment, Cairo, Egypt

*Corresponding author:

Ahmed MT Ghanem, Vascular Surgery Department, Nasser Institute For Research And Treatment, Cairo, Egypt

Citation: Ahmed MT Ghanem. Physician Modified Infusion Catheter (PMIC): An innovation to make catheter directed thrombolysis (CDT) more accessible. *Journal of Surgery and Research*. 7 (2024): 234-235.

Received: October 30, 2024

Accepted: November 11, 2024

Published: April 25, 2025

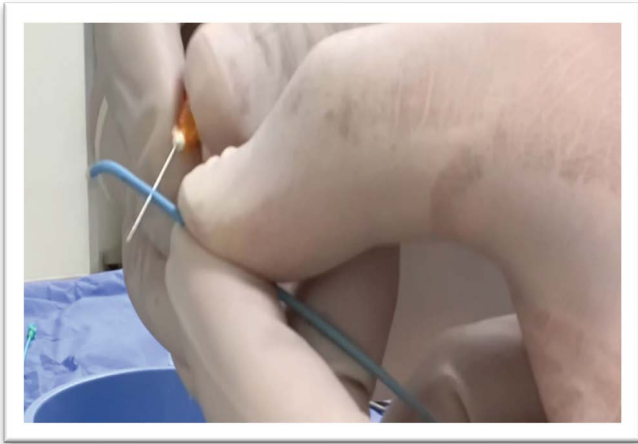


Figure 1: Creation of fenestrations in the catheter



Figure 2: Flushing the catheter with heparinized saline.

Finally, we have a physician modified infusion catheter that can be used immediately for the Catheter Directed Thrombolysis (CDT) (Video). We can use the same idea for creation of catheters with different shapes and purposes.

Funding & Disclosures

This paper is not under consideration elsewhere and none of the paper's contents have been previously published. The author of the paper named (Ahmed Mohamed Taher Ghanem) has read and approved the manuscript. There is no industrial or financial relationships to disclose. The author did not receive fund, grant or financial support from any company or related industry. I did not make consultations to any medical or pharmaceutical company.

Video Link: <https://youtu.be/n45GKoinOl8>

References

1. Sabrina D, Thomas K, Harm E, et al. Catheter Directed Thrombolysis for Not Immediately Threatening Acute Limb Ischaemia: Systematic Review and Meta-Analysis. *Eur J Vasc Endovasc Surg* 65 (2023): 537-545.
2. Dimitri T, Maria B, Stephania A, et al. Perioperative complications following major vascular surgery. Correlations with preoperative clinical, electrocardiographic and echocardiographic features. *Acta Biomed* 93 (2022): e2022255.
3. Yılmaz G, Isa S, Emrah E. Catheter-directed intra-arterial thrombolysis for lower extremity arterial occlusions. *Anatol J Cardiol* 22 (2019): 54-59.